

# A CAD System for Screening X-ray Chest Radiography

G. Horváth<sup>1</sup>, G. Orbán<sup>1</sup>, Á. Horváth<sup>1</sup>, G. Simkó<sup>1</sup>, B. Pataki<sup>1</sup>, P. Máday<sup>1</sup>,  
S. Juhász<sup>1</sup> and Á. Horváth<sup>2</sup>

<sup>1</sup> Budapest University of Technology and Economics, Department of Measurement and Information Systems, Budapest, Hungary

<sup>2</sup>Innomed Medical Inc. Budapest, Hungary

*Abstract*— The paper presents the first results of a Computer Aided Diagnosis (CAD) system development project for automatic evaluation of chest X-ray radiographs. The primary aim of the R&D project is to develop an intelligent advisory system for analyzing chest X-ray images and detecting lung nodules. This work has been started a few years ago and the CAD system will be used as an evaluation module of a digital X-ray lung disease screening system. The main steps of the research and development work is to segment the X-ray images according to the anatomical parts (determining the contours of lung, heart, clavicles and the rib cage) reducing the unwanted shadows (anatomical noise) of the bones and the heart, and detecting nodules and other abnormalities in the chest images. Research tasks are already in an advanced state, algorithms have been developed. First results on a moderate-size database are encouraging and we can expect further advances from the utilization of a large scale clinical testing that will start in the near future.

*Keywords*— Computer aided diagnosis, chest X-ray radiography, medical image processing,

## I. INTRODUCTION

Lung cancer is one of the most frequent causes of death throughout the world. The chance for curing cancerous cases can be increased significantly if the illness is detected at the early phase. The sooner the illness is detected, the more effective the treatment can be. Although there are controversial statements about the usefulness of X-ray chest radiography in lung cancer detection, today perhaps this is the only approach for cost-effective screening. A further important advantage of X-ray radiography chest screening is its relatively low radiation dose compared to the more sensitive approaches such as CT.

Although the most important goal of chest X-ray examination is lung nodule detection, chest screening can help to diagnose other illnesses such as pneumonia, emphysema, COPD, heart failure and other heart problems, etc.

The evaluation of X-ray chest images may be a rather difficult task even for skilled pulmonologists/radiologists. Computer aided evaluation of images needs complex image processing/pattern recognition algorithms, where first the images should be “cleaned” from disturbing parts, such as

the shadows of the bones (clavicles and the rib cage) and the heart to get such images where nodules can be detected more easily.

This means that the whole task of computer aided detection/diagnosis should be decomposed into many different subtasks: in the preprocessing phase the most important anatomical parts should be distinguished, the X-ray images should be segmented. The detection of abnormalities is done in the preprocessed images.

Preprocessing means that the contours of the lung fields and the heart, as well as the contours of the bones – the clavicles and the rib cage – should be determined. The findings of these contours may serve two goals: (1) the shape of these anatomical parts, especially the shape of the lung fields may have diagnostic meaning, (2) having determined the contours of the bones and the heart, there is a chance to suppress the shadows of these parts, “cleaning” the whole area of the lung fields, and making possible to “look behind” these parts. The suppression of the shadows of “disturbing anatomical parts” may significantly improve the performance of nodule detection, and may help in reducing false positive hits.

In certain existing CAD systems “bone-free” images are used applying dual energy technology [1], but suppressing the shadow of the heart can rarely be found – if it can be found at all – in chest X-ray CAD systems. The majority of commercial X-ray machines do not offer dual energy technology, moreover using dual energy technology the shadow of the heart cannot be removed, so finding an alternative approach still remains an important task. In this project a different approach is used to get a “clean” image. First the contours of the bones – the clavicles and the rib-system – and the heart are detected, than their shadows are removed resulting in a “clean” lung image.

The main goal of this project is to develop a decision support system that help radiologists/pulmonologists to detect various suspicious areas in chest radiograph. For this purpose a CAD system is being developed as an integrated part of an X-ray chest screening machine. The CAD system works on digital X-ray images, where the spatial resolution of the images is about 2000×2000 pixels, with (10-12)-bit gray levels per pixel.

In this paper first the problem of lung contour detection is discussed (Section II), then the approach applied for detecting the border of bones is presented (Section III). Sections IV and V deal shortly with the elimination of the shadows the bones and the heart, respectively, why Section VI deals with nodule detection.

## II. LUNG CONTOUR DETECTION

For lung contour detection many different approaches have been developed and validated. Among them one can find approaches based on edge detection with iterative contour adjustment, pixel classification, etc. Because of the great variability of the shapes of the lung fields acceptable results cannot be reached easily. The best results were achieved using active shape model (ASM) approach, similar to the algorithm presented in [2]. In ASM-based approach a statistical model is built [3] using many gold standard contours. For a given X-ray image the parameters of the model are adjusted until an optimal contour is obtained. The gold standard contours are obtained from the Japan Society of Radiological Technology (JSRT) data base [4]. An example of the result of the lung field contour detection can be seen in Fig. 1. In the figure both the gold standard and the obtained contours are shown.

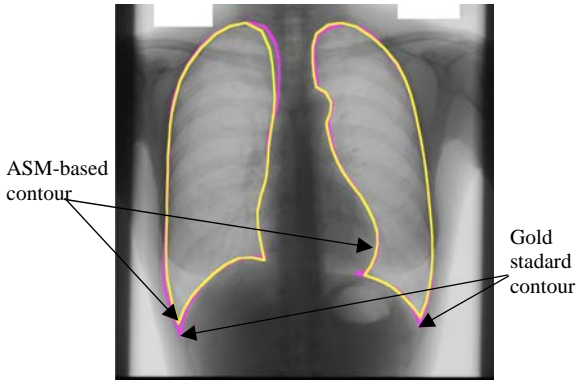


Fig. 1 The result of the lung field contour detection.

## III. CLAVICLE AND RIB CAGE DETECTION

Complete clavicle detection is probably an impossible task with the exclusive use of normal chest radiograph images. The medial epiphysis of clavicle produces an almost invisible, very dim shadow. This is the reason why we decided to try detecting only the diaphysis of the bone instead of detecting the whole bone.

Our clavicle detection is performed in three steps: preprocessing of the image, approximate curve fitting and pixel

precise detection. The first step of the clavicle detection is preprocessing of the X-ray images: the image is smoothed by a Gaussian filter, and then the edges are enhanced by multiplication with the gradient magnitudes. At the same time, incorrect gradient directions are suppressed: four different gradient images are created according to the four clavicle edges (upper and lower edges of the two clavicles). After preprocessing the position of the clavicles are estimated. As the contours of clavicles have very little curvature, we try to approximate them with straight lines. For this purpose we apply Radon transformation as it is a fast algorithm and works well even on noisy images.

The local maxima of the transformed image will specify lines through edges of the original image. However as ribs have similar characteristics as clavicles have, special care must be taken to find the latter. In most situations the clavicles have sharper edges than ribs and the clavicle edges are located in the upper part of the image.

We developed an iterative method that relies on these facts: the algorithm searches for edge pairs that belong to the highest Radon maxima and are in the most upper corner of the lung. We also filter the results with a simple criterion: only non-crossing edges are accepted if they are in an appropriate distance from each other. After finding the approximate contour lines, we try to determine the exact shape of the bones. Active contour modelling fits this task very well [5]. It applies minimization of an energy function representing the criteria mentioned before. A typical result of clavicle contour detection can be seen in Figure 2.

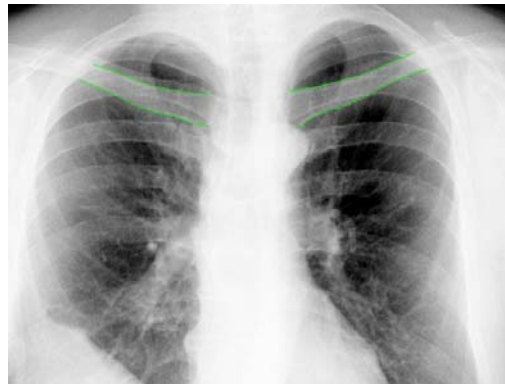


Fig. 2 The result of the clavicle contour detection.

For automatic detection of rib borders also many different approaches were developed. Using an approach similar to the clavicle detection method promising preliminary results could be obtained, however in the validation of the results using about 100 different images partly from the Japanese data base [4] and partly from a Hungarian database captured by a digital X-ray machine we found that the re-

sults are unacceptable at least in 50% of the images. A further possibility using model-based approach similar to the lung field contour detection - described in [6] – was also examined, however the results were also unsatisfactory. The present solution applies a complex algorithm where many rib contour candidates are generated and from these candidate curves the best ones are selected and adjusted until the best fit between the candidate curves and the rib contours can be reached. Fig. 3 shows a result image. Although in most of the images almost all rib contours are detected, in the figure it can be seen that there may be missing contours (the contours of the first rib).

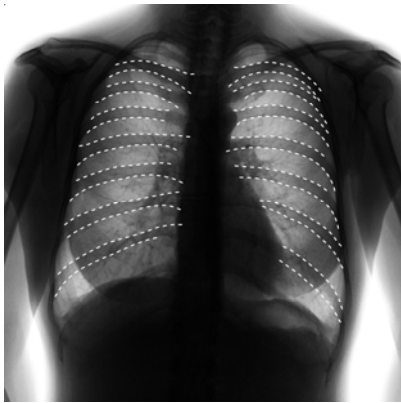

Fig. 3 A typical result of the rib contour detection algorithm.

#### IV. BONE SHADOW SUPPRESSING

Using the contours of the bones their shadows can be suppressed from the chest radiographs. The shadow compensating algorithm works in gradient image space. In the end the resulting images need to be transformed back into the normal image space. This means that we need an invertible gradient operator: the central difference operator in our case. Conceptually the main steps of the algorithm are:

- Calculating gradient image.
- Building statistical bone model.
- Recalculation the image from the modified gradient.

The essence of the algorithm is the creation of a statistical edge model, it does not use any a-priori information or machine learning. The gradients are evaluated along the bone edge and the model is built from the edge surroundings. After constructing the bone model, we subtract it from the original image, hence removing the shadow of the bone. Figure 4 shows the result of the algorithm in suppressing the shadow of a clavicle. The algorithm works well for rib cage shadow elimination too.

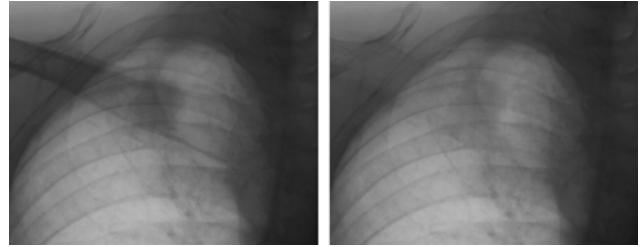


Fig. 4 Clavicle shadow suppression. Notice the nodule in the middle.

#### V. COMPENSATING THE SHADOW OF THE HEART

Compensating the heart shadow first of all needs an accurate contour of the heart. This task is partly solved determining the lung contours as the applied model-based algorithm results in the contour of the left lung field without the heart area. The mediastinum-side contour of the left lung field however also should be determined. Currently only a preliminary solution is obtained for this task, so this contour cannot be considered as an accurate one. Having determined the whole contour, the steps of the compensating algorithm are as follows:

- Calculate the average intensity of the area covered by the heart as a function of the distance from the mediastinum.
- Apply a smoothing filter for this distance-intensity function.
- Find maximal intensity and normalize the distance-intensity function.
- Compensate the intensity of the original image in the area covered by the heart according to the normalized distance-intensity function.

An example of the result of heart shadow compensation is shown in Figure 5.

#### VI. NODULE DETECTION

The major task of lung CAD systems is the localization of cancerous regions on chest radiographs. The suspicious regions on the input images are marked, decreasing the load on the diagnosing specialist, who is able to pay more attention to these areas throughout the examination. However, it is also quite important to avoid marking regions needlessly, in order to avoid confusing results. By suppressing the shadows of the bones and the heart, the characteristics of underlying tissues become more observable.

The algorithm improves the recognition rate in two different ways. First of all, the amount of true positives is in-

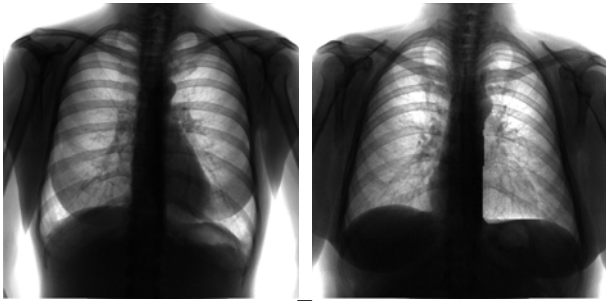


Fig. 5 Heart shadow elimination

creased. Additionally the algorithm helps reducing the number of false positives. On some images the shadow of the overlapping parts of the clavicles and the ribs, may seem similar to that of the nodules so nodule detection algorithm may mark these parts as suspicious regions. In the worst case the classifier may fail to recognize this situation that results in a false positive marking. By considering the known anatomical properties, it is possible to remove the misleading signs of the clavicle region that prevents this scenario.

Nodule detection is applied only in the lung field areas. Within these areas candidate regions – regions of interest, ROIs – are selected, which may contain abnormalities. As the classifier algorithm in the next step is responsible for the selection of the true positive areas, the aim of the ROI selection step is to mark all the suspicious areas.

As cancerous regions on radiographs appear mainly as rounded ones with relatively smooth boundary, the main requirements for the algorithm is to find each object on the image with these properties. Additional requirements need to be considered however, as the nodule sizes may vary significantly, and the cancerous regions are often really hard to observe due to their weak contrast to the background.

One approach to fulfil these requirements is to apply a filter from the Convergence Index (CI) family, such as Sliding Band Filter [7]. CI filters apply a criterion related to the directional properties of the image gradients, and are able to increase contrast insensitively. Sliding Band filters additionally are able to recognize nodules with a wide variety of sizes due to the adaptive selection of the region boundaries applied. The candidate regions are selected by thresholding. The last step of the nodule detection algorithm is the application of a classifier. The classification of candidate regions is based on the selected image features describing the properties of the ROI by characterizing it in different scales. The local properties are described by textural features, based mainly on statistical measures, while the geometrical features, like the characteristics of the contour of the ROI, represent the image properties of larger scale. The selection

of the appropriate set of features was done by a feature relevance determination method described in [6].

The selected classifier is a Support Vector Machine (SVM), as SVMs are well known for their ability to deal with high dimensional input data, and for their robustness.

The classifier is trained on samples from the JSRT database, as it serves as a standard benchmark dataset. Separate experiments tested bone detection and suppression, and the improvement on nodule detection. We used two sets of chest radiographs for test purposes: the standard JSRT database and 108 additional images.

## VII. CONCLUSIONS

In this paper we gave a short description about a CAD system for supporting medical decision making for X-ray chest radiography. Complex algorithms for the most important subtasks have been developed using standard image database. Currently the CAD system is being built into an X-ray chest screening system. Extensive medical testing of the results are coming in the next few months.

## VIII. ACKNOWLEDGEMENT

This work was partly sponsored by Hungarian Development Agency under contract KMOP-1.1.1-07/1-2008-0035

## REFERENCES

1. Lehmann et al. (1981). Generalized image combinations in dual KVP digital radiography. *Medical Physics* 8 (5), pp. 659–667.
2. Cootes, T.F., Taylor, C.J., Cooper, D., Graham, J., (1995). Active shape models – their training and application. *Comp. Vision and Image Understanding* 61 (1), 38–59.
3. B. van Ginneken, M. B. Stegmann and M. Loog (2006) Segmentation of anatomical structures in chest radiographs using supervised methods: a comparative study on a public database. *Medical Image Analysis* 10 19–40
4. Japanese Society of Radiological Technology: Digital Image Database. [http://www.jsrt.or.jp/web\\_data/english03.php](http://www.jsrt.or.jp/web_data/english03.php)
5. B. van Ginneken (2001) Computer-Aided Diagnosis in Chest Radiography, PhD thesis, University of Utrecht
6. Kass, M., Witkin, A., Terzopoulos, D. (1987), Snakes: Active Contour Models. *Int. Journal of Computer Vision*, 1. (4), pp. 321-331.
7. Wei; Hagihara, Y.; Kobatake, H. (1999). Detection of cancerous tumors on chest X-ray images—candidate detection filter and its evaluation. *Proc. of the International Conf. on Image Processing, ICIP 99.*

Author: Gábor Horváth  
 Institute: Budapest University of Technology and Economics  
 Street: Magyar tudósok krt. 2  
 City: Budapest  
 Country: Hungary  
 Email: horvath@mit.bme.hu